

## Case Report

# Eviscerated 'Amyand' Incisional Hernia

Soumen Das, MBBS, MS;<sup>1</sup> Sudip Sarkar, MBBS, DLO;<sup>2</sup>

Mriganka Ghosh, MBBS, MS;<sup>2</sup> Utpal De, MBBS, MS<sup>2</sup>

<sup>1</sup>Institute of Post Graduate Medical Education and Research

Department of Surgery

Seth Sukhlal Karnani Memorial Hospital

<sup>2</sup>Department of Surgery,

Nilratan Sircar Medical College and Hospital

Kolkata, India

### Abstract

The presence of an inflamed appendix in an inguinal hernia sac is known as "Amyand" hernia. The appendix within an umbilical incisional hernia sac is rare, and its evisceration is even rarer. Here we report a case of spontaneous evisceration of an appendix through an umbilical incisional hernia following laparoscopic cholecystectomy.

**Key words:** Hernia, appendix.

### Introduction

An inflamed appendix as a component of inguinal hernia is a rare entity. It was first described by Claudius Amyand in 1735.<sup>1</sup> However, the presence of the appendix in an incisional hernia sac is more rare. Its evisceration has not been reported in English literature.

### Case Report

A 53-year-old woman presented to the surgery emergency department of Medical College, Kolkata, with severe abdominal pain and protrusion of a tube-like structure through a large ventral hernia, which she harbored for two years. Pain onset was sudden. It was initially located over the hernia but later involved the whole abdomen. She was obstipated for one day with nausea and anorexia. She had a history of laparoscopic cholecystectomy performed five years prior to the incident. Upon examination, she was a poorly nourished and screaming from abdominal pain. Her pulse rate was 100 per minute with a

blood pressure level of 104/70 mmHg. Her abdomen was distended with a huge umbilical hernia. The skin over the hernia was thickened and blackish with areas of ulceration. A tube-like intra-abdominal structure was protruding through an ulcerated area (Figure 1).

Intestinal peristaltic sounds were absent. Rectal examination revealed an empty rectum. The patient was resuscitated with intravenous fluid and nasogastric decompression, and then she was taken to the emergency operation theater. The hernia was explored with an infraumbilical smiling incision. An inflamed appendix, part of the cecum, and terminal ileum were found as contents of the sac. The intestine appeared viable and was returned to the abdominal cavity. An appendectomy was performed. The adhesions involving the bowel and the hernia sac were released. The fascia was widely dissected, and the edges were overlapped and sutured with nonabsorbable (polypropylene) suture. The redundant skin and the hernia sac were resected (Figure 2). A suction drain was placed in the subcutaneous plane.

The postoperative period was uneventful. The drain was removed on the second postoperative day,

Correspondence should be directed to

Soumen Das, MBBS, MS

e-mail: drsoumen\_das@yahoo.co.in

and the patient was discharged on the sixth postoperative day.

### Discussion

Incisional hernia through an umbilical port following laparoscopic cholecystectomy is not uncommon. Its reported incidence is 0.8%.<sup>2,3</sup> In addition to technical factors such as the method of fascia closure, postoperative infection, poor nutrition, and a patient's abdominal musculature are additional factors in the causation of incisional hernia. An umbilical hernia usually contains omentum or small bowel, but rarely has the presence of an appendix been reported.<sup>4</sup> Amyand hernia describes the presence of inflamed appendices in inguinal hernias,<sup>1</sup> but an appendix in incisional hernia does not have a specific name.

Spontaneous evisceration of hernia contents is rarely encountered, but is mostly associated with chronic dermatitis, trophic ulceration, or liver cirrhosis with ascites.<sup>5-8</sup> Management of eviscerated hernia demands urgent exploration aimed at the prevention of strangulation. The operative principles are repositioning the content or resection (if already gangrenous), excision of the redundant sac and skin, followed by repair of the hernia. In the presence of infection prosthetic repair is best avoided, however, the chance of recurrence remains.<sup>5,9</sup> Because an inflamed appendix was present in the hernia of the aforementioned case, Mayo's anatomical repair (double breasting of the fascial edges) was performed.<sup>10</sup>

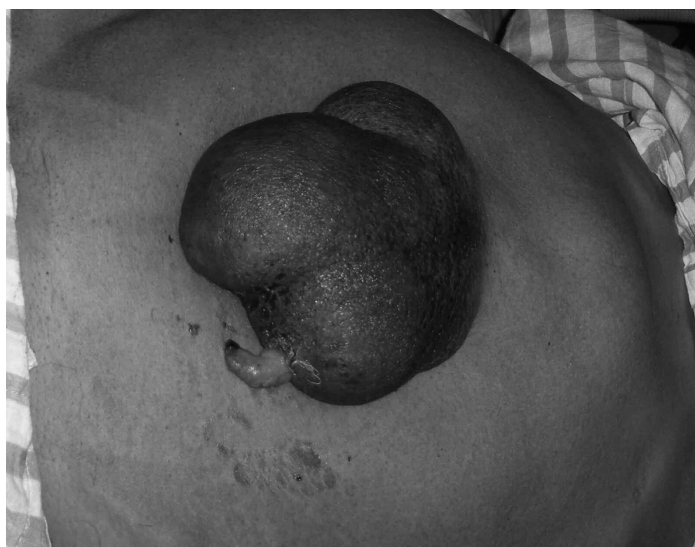### Conclusion

This is the first published report in English of an eviscerated inflamed appendix in an umbilical incisional hernia following laparoscopic cholecystectomy. When encountered, early surgical intervention with definitive repair is the treatment of choice for an eviscerated Amyand incisional hernia.

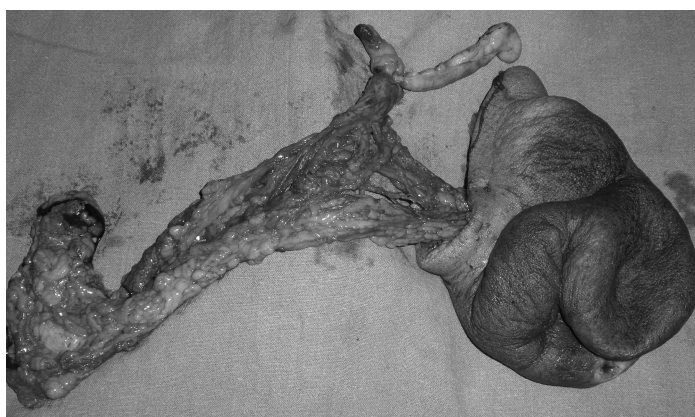
*Editor's Note: Additional figures are available as supplementary files at <http://jima.imana.org/article/view/8069>.*

### References

1. Amyand C. Of an inguinal rupture, with a pin in the appendix coeci, incrustrated with stone; and some observations on wounds in the guts. *Phil Trans Royal Soc.* 1736;39:329.



**Figure 1. Evisceration of appendix through large umbilical hernia.**



**Figure 2. Resected specimen: redundant skin, appendix, and part of omentum.**

2. Carey LC. Acute appendicitis occurring in hernias: a report of 10 cases. *Surgery.* 1967;61:236-8.

3. La Mura F, Cirocchi R, Farinella E, et al. Emergency treatment of complicated incisional hernias: a case study. *Ann Surg Innov Res.* 2009;3:15. Available from: <http://www.asir-journal.com/content/3/1/15>.

4. Voitk AJ, Tsao SG. The umbilicus in laparoscopic surgery. *Surg Endosc.* 2001;15:878-81.

5. Lemmer JH, Strodel WE, Knol JA, et al. Management of spontaneous umbilical hernia disruption in the cirrhotic patient. *Ann Surg.* 1983;198:30-4. Available from: <http://www.ncbi.nlm.nih.gov/pmc/articles/PMC1352927/>.

6. Zaz MA, Dass T, Muhee A, et al. An unusual case of inguinal hernia with spontaneous evisceration. *Hernia.* 2010. Available from: <http://dx>.

---

[doi.org/10.1007/s10029-010-0710-z](https://doi.org/10.1007/s10029-010-0710-z).

7. Terranova SA, Siddiqui KM, Preminger GM, et al. Hand-assisted laparoscopic renal surgery: hand-port incision complications. *J Endourol*. 2004;18:775-9.

8. Ginsburg BY, Sharma AN. Spontaneous rupture of an umbilical hernia with evisceration. *J Emerg Med*.

2006;30:155-7.

9. Chochinov H. "Spontaneous" umbilical evisceration. *J Pediatr Surg*. 1980;15:670-1.

10. Farthmann EH, Mappes HJ. Der spannungsfreie Verschluss der Narbenhernie. *Chirurg*. 1997; 68:310-6.