

Type VI choledochal cyst revisited

De U, Das S, Sarkar S

ABSTRACT

Choledochal cysts are rare cystic dilatations of the bile ducts, which are commonly found in children. Choledochal cysts in adults are uncommon, and cystic dilatation of the cystic duct (type VI choledochal cyst) is a unique occurrence. To date, specific pathogenic and diagnostic criteria for describing type VI cysts have been lacking. This report attempts to lay down the specific diagnostic and management criteria of this uncommon entity, with reviews of all available cases reported in the literature.

Keywords: choledochal cyst, cystic duct

Singapore Med J 2011;52(5):e91-e93

INTRODUCTION

Choledochal cysts (CDC) are cystic dilatations of the biliary ducts, with an incidence of 1 in 100,000–150,000 in Western countries and 1 in 1,000 in Asian populations.⁽¹⁾ The male to female ratio varies from 1:3 to 1:4.⁽¹⁾ The primary classification of Alonso-Lej, later modified by Todani, describes five variants of the disease.^(1,2) The sixth variant of isolated dilatation of the cystic duct was described by Loke et al.⁽³⁾ An extensive search of medical databases has revealed a few isolated case reports of this rare entity.⁽¹⁻⁶⁾ This is a theoretical attempt to amalgamate the findings of published reports and to specify this entity based on specific criteria.

CASE REPORT

An 18-year-old female patient presented with recurrent right upper abdominal pain and intermittent jaundice for six months. Her past history was insignificant, and she had normal bladder and bowel habits. She had no history of addiction or allergies to any drug or food. Clinical examination revealed mild icterus and tenderness over the right hypochondrium. Examinations of the abdomen and other systems were normal.

Baseline investigations revealed the following: haemoglobin 12 gm%; total count 8,700 (N 64, L 31, M 1, B 0, E 4); fasting glucose 90 mg/dl; urea 28 mg/dl; and creatinine 0.6 mg/dl. Liver function test showed bilirubin 6.37 mg/dl (Direct –3.74 mg/dl) and alkaline phosphatase 354 u/l (normal 0–31 u/l). Aspartate aminotransferase, alanine aminotransferase, amylase and lipase were within

normal limits. Hepatitis viral markers were negative. Chest radiography and electrocardiogram were normal.

Ultrasonography (USG) revealed a distended gall bladder with a thick wall and intraluminal sludge. The common bile duct (CBD) measured 7 mm in the porta. A well-defined, thick-walled fusiform cystic lesion (54 mm × 34 mm) was noted in the distal CBD. The cyst contained microcalculi and sludge, possibly collecting duct carcinoma (CDC). Magnetic resonance cholangiopancreatography (MRCP) with 3-dimensional thin-section, thick-slab and maximum intensity projection techniques showed a distended gallbladder and no intraluminal lesion. The right and left hepatic ducts appeared normal, with fusiform dilatation (maximum diameter of 41 mm) and a normal distal CBD suggestive of CDC of the proximal CBD (Fig. 1).

Based on the above findings, the patient was explored by roof-top incision. On exploration, a normal confluence and common hepatic duct (CHD) with a dilated cystic structure was found adjacent to the CHD and compressing it. The gallbladder was noted to open into the cyst via a narrow duct. Further dissection revealed that the cyst opened into the CBD with a wide mouth and normal distal CBD. The distal CBD was explored up to the junction of the CBD and pancreatic duct. The cyst was separated from the CHD and the junction of the CHD, and then the cyst was delineated. It was at this juncture that a diagnosis of type VI CDC (isolated dilatation

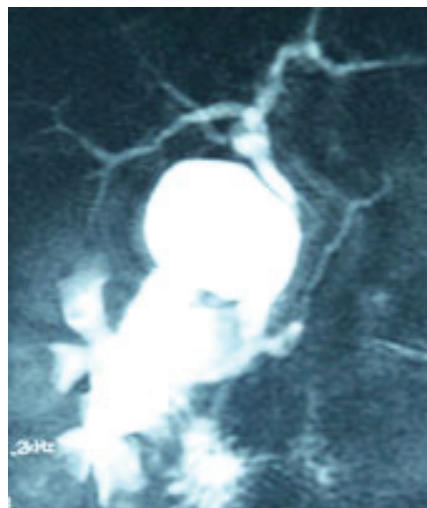


Fig. 1 MRCP image shows cystic dilatation of the cystic duct communicating with the common bile duct.

**Department of Surgery,
Calcutta Medical College,
88 College Street,
Kolkata 700073,
West Bengal,
India**

De U, MS, DipLS,
DipOrth
Associate Professor

Das S, MS
Postgraduate Trainee

Sarkar S, MS
Postgraduate Trainee

Correspondence to:
Dr Utpal De
(91) 33 943415 6664
(91) 33 3295 0700
Email: utpalde@
vsnl.net

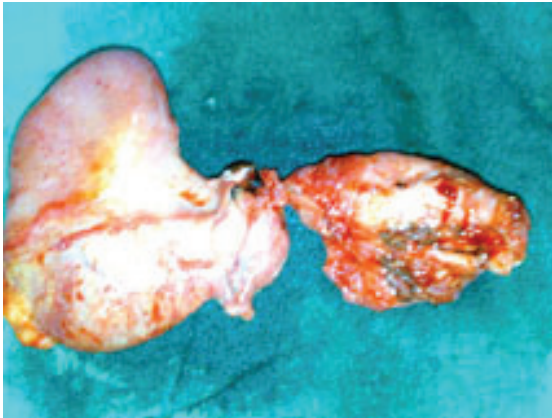

Fig. 2 Photograph shows a specimen of the gallbladder with a choledochal cyst of the cystic duct.

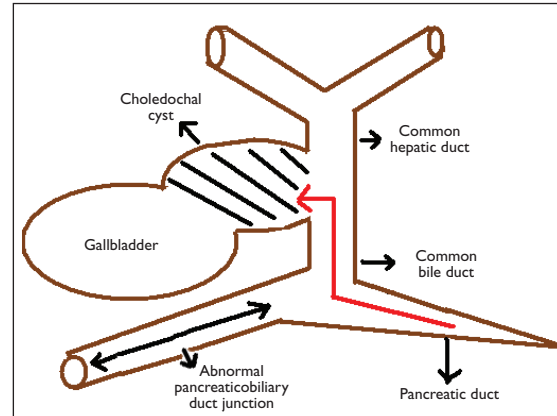


Fig. 3 Schematic diagram shows the proposed mechanism for formation of type VI choledochal cysts.

of the cystic duct) was made. The cyst, along with the gallbladder and distal CBD (Fig. 2) was excised, and hepaticoenterostomy was performed. Postoperatively, the patient developed a low-output biliary fistula, which was managed conservatively. She recovered satisfactorily and was discharged on postoperative Day 14 after stitch removal. Histopathology revealed biliary epithelium with tall, flat papillary structures and increased cellularity, round nuclei, fine and homogeneously distributed chromatin with intraepithelial neutrophil infiltrations that were consistent with CDC. At the six-month follow-up, the patient was doing well.

DISCUSSION

A wider consensus on the pathology, classification, diagnosis and management of cystic duct has been outlined but has yet to be formalised. Isolated dilatation of the cystic duct has been classified as a subtype of type II, although some authors consider it to be a distinct type VI variant.⁽⁶⁾ Isolated dilatation of the cystic duct may be simple cysts, duplication cysts or CDC.⁽¹⁾ 80% of CDC occurs in patients below ten years of age. Patients older than 12 years of age who suffer from CDC are deemed to be adult CDC cases.⁽¹⁾ Most patients suffering from isolated dilatation of the cystic duct are adults.⁽²⁻⁶⁾ The common presentations are abdominal pain and jaundice.

Although many aetiologic factors have been proposed, type VI CDC has some specific anatomic abnormalities that support the belief that abnormal pancreaticobiliary duct junction (APBDJ) is the most likely cause.⁽²⁻⁶⁾ Acute angulation of the CHD and cystic duct junction, together with a wide opening of the cystic duct and APBDJ, triggers the reflux of pancreatic juice (Fig. 3).⁽¹⁾ The mixing of pancreatic juice and bile as well as stasis results in cystic duct ectasia. This

sometimes gives a picture akin to Mirizzi syndrome.⁽⁶⁾ Moreover, fluid aspirated from the cyst is rich in lipase, which points to CDC.⁽¹⁾ Most of the reported cases have normal intra- and extrahepatic biliary ductal systems, which indicate a distinct pathology. The reason for isolated involvement of the cystic duct excluding the CBD is unclear; possibly, the junction of the cystic duct, with the CBD being the weakest part due to the least vascularity, causes an ectatic change that continues as a vicious cycle, resulting in further dilatation.⁽¹⁾ This in turn increases the angulation of the already abnormal CHD and cystic duct junction, thereby increasing reflux into the already dilated sac and causing mass effect on the CHD and CBD. Focal aganglionosis akin to Hirschsprung disease could also result in isolated dilatation of the cystic duct.⁽¹⁾ Raised pressures within the cyst and distal CBD are also noteworthy. Microlithiasis is present in 8% of cases of CDC, and this fact remains in most type VI CDC.⁽¹⁻⁶⁾

Preoperative diagnosis of type VI CDC is challenging. Although radiologic modalities are able to clearly demonstrate CDC, a precise diagnosis of type VI CDC is difficult unless the operator is well acquainted with the condition. Most cases have been mistaken either as type I or type II CDC.⁽⁷⁾ As such, all the reported cases were diagnosed intraoperatively. Our patient was also diagnosed intraoperatively, but a retrospective analysis of the MRCP plates clearly demonstrated the pathology. Typical radiologic abnormalities that are specific to type VI CDC include dilatation and squaring of the cystic duct, acute angulation of the CHD and cystic duct junction with a distinct plane present between the dilated cystic duct and CHD, a normal or wide (Mirizzi syndrome) opening of the cystic duct to the CBD, a normal CBD and associated APBDJ.

The management of type VI CDC depends on the opening of the cystic duct to the CBD.^(2-6,8) If the opening is normal, a simple cholecystectomy, either open or laparoscopic, is sufficient.⁽³⁾ With a wide Mirizzi-type opening, excision of the cyst along with lower CBD and followed by hepaticoenterostomy is optimal.⁽⁶⁾ This should preferably be undertaken by open procedure so as to avoid complications. All specimens should be sent for histology, paying close attention to the presence of biliary intra-epithelial neoplastic (BIN) changes.⁽⁸⁾ With a positive diagnosis of BIN, patients who had undergone simple cholecystectomy should redo the procedure, with excision of the extrahepatic biliary tract by hepaticoenterostomy. The patient should be followed up with hepatobiliary imino-diacetic acid imaging in the early postoperative period, and thereafter, with yearly USG/liver function tests to detect any complications.

To conclude, type VI CDC is an extremely rare variety of adult CDC. The age of onset of disease ranges from 18 to 52 years. It is predominantly found in women. The common presentations include abdominal pain and jaundice. Preoperative radiological diagnosis is challenging, and gall stones (microlithiasis) may

be found within the cyst. The differential diagnosis is Mirizzi syndrome. The opening of the cystic duct into the CBD dictates the operative procedure. Postoperative histopathology should specify the presence or absence of BIN, and postoperative follow-up is mandatory.

REFERENCES

1. Singham J, Yoshida EM, Scudamore CH. Choledochal cysts: part 1 of 3: classification and pathogenesis. *Can J Surg* 2009; 52:434-40.
2. Bode WE, Aust JB. Isolated cystic dilatation of the cystic duct. *Am J Surg* 1983; 145: 828-9.
3. Loke TK, Lam SH, Chan CS. Choledochal cyst: an unusual type of cystic dilatation of the cystic duct. *AJR Am J Roentgenol* 1999; 173:619-20.
4. Serena Serradel AF, Santamaria Linares E, Herrera Goepfert R. Cystic dilatation of the cystic duct: a new type of biliary cyst. *Surgery* 1991; 109:320-2.
5. Bresciani C, Gama-Rodrigues J, Santos VR. Video-laparoscopic treatment of a sizeable cyst of the cystic duct: a case report. *Surg Laparosc Endosc* 1998; 8:376-9.
6. Conway WC, Telian SH, Wasif N, Gagandeep S. Type VI biliary cyst: report of a case. *Surg Today* 2009; 39:77-9.
7. Singham J, Yoshida EM, Scudamore CH. Choledochal cysts: part 2 of 3: Diagnosis. *Can J Surg* 2009; 52:506-11.
8. Singham J, Yoshida EM, Scudamore CH. Choledochal cysts. Part 3 of 3: management. *Can J Surg* 2010; 53:51-6.